

Case Report of a Rare Rectal Squamous Cell Carcinoma

Otero RC*, Polavarapu H and McCain DA

Department of Anesthesiology, USA

***Corresponding author:**

Raquel Cancho Otero, Department
of Anesthesiology, USA, E-mail:
raquel.cancho@hmn.org

Received: 01 Jul 2022

Accepted: 11 Jul 2022

Published: 16 Jul 2022

J Short Name: AJSCCR

Copyright:

©2022 Otero RC, This is an open access article distributed under the terms of the Creative Commons Attribution License, which permits unrestricted use, distribution, and build upon your work non-commercially.

Citation:

Otero RC. Case Report of a Rare Rectal Squamous Cell Carcinoma. *Ame J Surg Clin Case Rep.* 2022; 5(3): 1-3

1. Background

Rectal squamous adenocarcinoma is a rare primary rectal malignancy compared to the common colorectal adenocarcinoma. Due to the low incidence of this cancer at 0.1% the pathogenesis and risk factors are based on few case reports and case series [7]. It is believed to be directly linked to the complex inflammatory process caused by the Human Papilloma Virus (HPV), specifically serotype 16 and 18 [3]. Here we present a case report on a 45-year-old female who was found to have a distal mass that required careful pre-operative planning to complete surgical intervention with R0 resection. Her past medical history includes a complex sclerosing breast lesion with abnormal fibrocystic changes s/p lumpectomy, but HPV negative who presented with over 6 months of constipation that recently worsened to include rectal bleeding. Imaging revealed a distal circumferential mass that was compressing the rectum. Biopsy revealed poorly differentiated squamous rectal adenocarcinoma. Ultimately the patient needed neoadjuvant therapy and surgery intervention, which required lysis of adhesions, resection of omentum, takedown of splenic flexure and subtotal proctectomy. Exophytic squamous rectal adenocarcinoma varies in general GI symptoms and the distal location makes it difficult to resect. The prognosis and probability of surgical intervention depends on early staging, size of neoplasm, and invasion of nearby structures. In this case, R0 resection was successfully performed.

Rectal squamous adenocarcinoma is associated with HPV, STDs, history of anal intercourse, HIV, presence of precancerous anal lesions such as condylomas or high grade intraepithelial anal/cervical/vulvar/vaginal neoplasia, and smoking. This subtype of anal cancer is extremely rare. Its tumor size, nodes, and metastasize as well as clinical staging determines patient prognosis.

Male gender and HIV positive status may be an unfavorable long-term outcome [8].

2. Case Presentation

A 45-year-old female with a past medical history of complex sclerosing breast lesion with proliferative fibrocystic changes s/p lumpectomy in 2018 presented to the Medical Oncology team in Hackensack University Medical Center, NJ with longstanding constipation with no relief from suppositories and a month of rectal bleeding. She underwent a colonoscopy on 11/13 which showed a circumferential, frond-like fungi ulcerative partial obstructing mass in the proximal rectum. Biopsy revealed moderate to poorly differentiated invasive squamous cell carcinoma (Figure 1). She had a subsequent CT scan revealing a right-sided rectal mass 2.9 x 3.5 cm, which appears largely exophytic and was compressing the rectum. There were some adjacent mesorectal lymph nodes 5 and 9 mm in size. She had a myomatous uterus seen as well as a functional right ovarian cyst. She then underwent an MRI of the rectum revealing a mass 10.4 cm from the anal verge that appeared to be primarily extra-rectal, again 3.7 x 2.8 cm in greatest dimension with some small adjacent 7 mm mesorectal lymph nodes. Given the uncommon biopsy result of rectal squamous cell carcinoma further investigation was done to rule out the possibility of it being a secondary tumor/metastasis. Studies have shown a correlation between Human Papilloma Virus and various squamous cancers. Patient was referred to her gynecologist and she states she has not had an abnormal pap smear result or HPV. Her PET did not reveal another site of disease, and nodes were negative. Her GYN exam and HPV negative. Patient was diagnosed with rectal squamous cell carcinoma staged at T3N1 (N0 by PET). Plan was to start chemotherapy of Xeloda on days of radiation and Cisplatin and to be evaluated by surgery for possible tumor resection. After chemo was completed a follow up MRI was done on 3/2021 which showed no residual tumor. Given her rare malignancy, the patient consented to a repeat colonoscopy and surgery to eliminate the possibility of recurrence.

In the operating room, a foley catheter was placed and the patient was placed in a lithotomy position. Prior to prepping the perineum, rigid sigmoidoscopy performed revealing an area of firmness in the area tattooed consistent with the previous location of the rectal cancer.

Exploratory laparoscopy was performed; making a periumbilical incision through which a Veress needle inserted. The abdominal cavity insufflated with CO₂ gas pressure of 15 mmHg, followed by 5-mm trocar and 5-mm 30-degree

laparoscope. Surgery was difficult as it was noted patient had relatively fatty internal components with extensive fatty omentum and multiple enlarged appendices epiploic in the colon, and dilated right colon, which extended across to the left side in the operative field. The patient was placed in reverse Trendelenburg position, to evaluate the colon and then placed in Trendelenburg for evaluation of adhesions extending down towards the pelvis. Lysis of adhesions in the lateral left quadrant were done. The surgery was converted to open and an excision was done in her previous abdominal scar from a prior ectopic pregnancy. Following this, a midline incision 16 cm above the umbilicus down to pubic symphysis was done. The descending colon was mobilized to better access the splenic flexure. Small bowel was retracted away from the area and with use of the Impact LigaSure device direct takedown of the splenic flexure was done to increase the mobilization of the descending and distal transverse colon to allow for pelvic anastomosis. It was also noted the uterus had multiple leiomyomas and a St. Marks retractor was used to retract it away.

Identification of right and left ureters were done to preserve it and middle hemorrhoids were taken down with the Impact LigaSure device. The Posterior perirectal space was dissected out down to the level of the visibility of the tattoo extending down below the peritoneal reflection towards the mid to distal rectum. Following this, rigid sigmoidoscopy was reperformed to confirm that the site for transection would incorporate all the areas of inking seen within the rectum. Transection of the descending left colon with resection of the sigmoid colon and extending down to proximal to mid-rectum for a subtotal proctectomy transection at the base of the rectum was conducted with GIA stapler. The specimen was removed, opened, and gross examination inking was noted within the specimen. A colotomy incision was done to place the anvil in the descending colon and was placed down to the pelvis. Then the EEA stapler was placed through the rectum noted at the distal stump and the end-to-end low pelvic anastomosis was conducted. Exparel was then used for the abdominal wall rectus sheath nerve block, followed by subsequent complex plastic closure of the anterior abdominal wall. The postoperative course was uneventful, and the patient was kept NPO. Once pain was well-controlled, tolerated diet, and she displayed normal bowel function, the patient was discharged three days later (Figure 2).

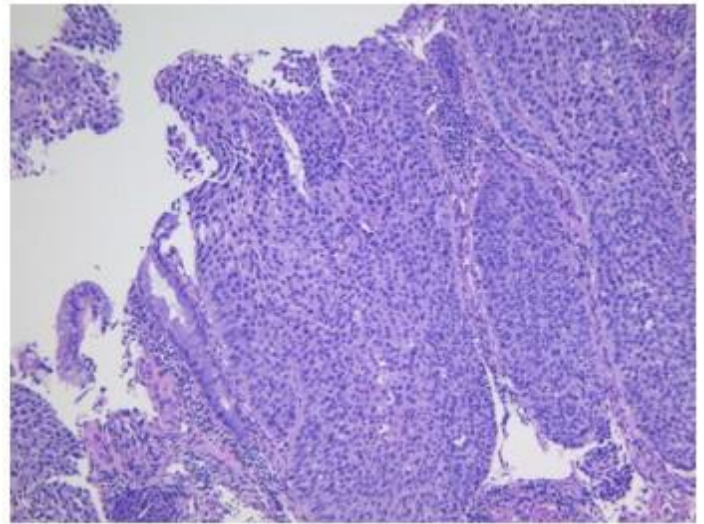


Figure 1: Biopsy revealed moderate to poorly differentiated invasive squamous cell carcinoma

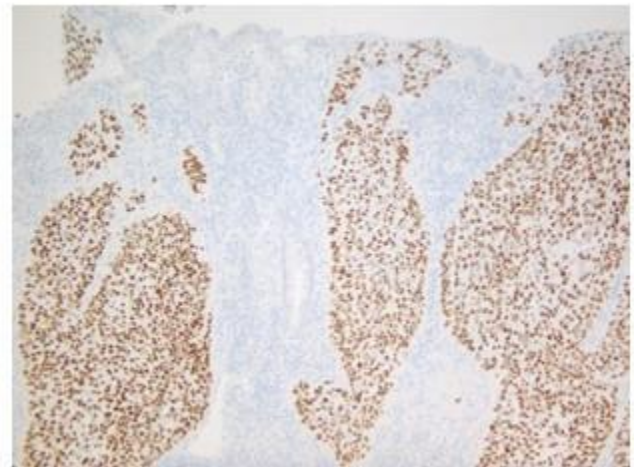


Figure 2: subsequent complex plastic closure of the anterior abdominal wall

3. Discussion

Cancer of the colon and rectum is the third leading cause of cancer related deaths in the United States, with an estimated incidence of 149,500 (7.9% of all new cancer cases) and 52,980 deaths (8.7% of all cancer related deaths) in 2021 [1]. Squamous cell carcinoma of the colon and rectum, whether primary or metastatic, is an extremely rare presentation, accounting for less than 1% of colorectal cancers. Normal colorectal tissue is composed of glandular epithelium and while squamous epithelium is found in tissue of the anus, it is unusual for it to be localized more proximally. While the pathophysiology and risk factors of colorectal adenocarcinoma are well known, those of squamous cell carcinoma are not as well understood. Current literature has proposed several potential mechanisms. These include improper differentiation of precursor cells in the colonic epithelium, metaplastic changes secondary to chronic pathological (ulcerative colitis, iatrogenic radiation injury, etc.) or mechanical irritation, and infection [2, 3].

Clinical presentation of colorectal SCC in the patient included chronic rectal bleeding and constipation for multiple weeks. This presentation is nonspecific and is similar to that of many other pathologies including adenocarcinoma, solitary tumors, and inflammatory bowel disease among other conditions. Furthermore, given the patient's age, absence of family history of colorectal cancer, and negative genetic predisposition, the diagnosis was improbable. Poorly differentiated squamous cell carcinoma in other systems is well documented to be aggressive with varying factors that impact prognosis, namely stage and grade [4]. Prognosis has been shown to decrease with increase in stage, poor differentiation, and nodal spread. This highlights the role of colonoscopy and CT scan in localizing the mass and excisional or incisional biopsy in correctly distinguishing the pathology from adenocarcinoma in the patient.

The patient was diagnosed with T3N1 cancer with a PET scan showing no distant metastasis or malignancies anywhere else in the body. Due to the rarity of colorectal squamous cell carcinoma, there is a scarcity of literature studying prognostic factors, interventions, and patient outcomes for colorectal squamous cell carcinoma [5, 6]. However, multiple case reports have shown that surgical intervention has been successful in numerous patients with no recurrence. We believe given the patient's tumor burden and no sign of metastasis, surgical resection was therapeutic despite the technical difficulty of the procedure.

Future studies are needed to further explore potential causes of squamous cell carcinoma in the colon and rectum, as well as quantify outcomes for surgical intervention. Furthermore, other therapies such as chemoradiotherapy and pharmacological agents should be evaluated to see if they could potentially have a role in treating more severe and disseminated forms of this malignancy.

4. Conclusion

We report a 45-year-old female presenting with a large, exophytic, circumferential, ulcerative obstructing mass in the proximal rectum that was identified as a T3N1 squamous rectal carcinoma requiring a Rigid sigmoidoscopy, exploratory laparoscopy, lysis of adhesions, exploratory laparotomy, takedown of splenic flexure colon, left colectomy, sigmoid colectomy, subtotal proctectomy, low pelvic anastomosis, abdominal wall rectus sheath block, and complex plastic closure. Surgical intervention was ultimately therapeutic despite the technical difficulty of achieving resection.

5. Acknowledgment

The patient has provided written informed consent for publication of their clinical details and/or clinical images. A copy of the consent is available for review by the Editor of this journal.

References

1. National Cancer Institute's Division of Cancer Control and Population Sciences. Surveillance, epidemiology, and end results program. In: Cancer of the colon and rectum. SEER; 2021. Web. 20 Oct 2021.
2. Gelas T, Peyrat P, Francois Y, Gerard JP, Baulieux J, Gilly FN, et al., Primary squamous-cell carcinoma of the rectum: report of six cases and review of the literature. *Diseases of the colon and rectum*. 2002; 45: 1535–40.
3. Makadia S, Patel I, Abusaada, K. Human Papillomavirus Positive Squamous Cell Carcinoma of the Rectum. *Cureus*. 2020; 12: e9022.
4. Frizelle FA, Hobday KS, Batts KP, Nelson, H. Adenosquamous and squamous carcinoma of the colon and upper rectum: a clinical and histopathologic study. *Diseases of the colon and rectum*. 2001; 44: 341–6.
5. Williams GT, Blackshaw AJ, Morson BC. Squamous carcinoma of the colorectum and its genesis. *The Journal of pathology*. 1979; 129: 139–47.
6. Abdelqader A, Jabaji R, Albugeay M, Palese C. Squamous cell carcinoma of the ascending colon: two cases. *Journal of community hospital internal medicine perspectives*. 2017; 7: 53–5.
7. Dyson T, Draganov PV. Squamous cell cancer of the rectum. *World journal of gastroenterology*. 2009; 15: 4380–6.
8. Roberts JR, Siekas LL, Kaz AM. Anal intraepithelial neoplasia: A review of diagnosis and management. *World journal of gastrointestinal oncology*. 2017; 9: 50–61.