

Segmental Resection for Congenital Esophageal Stenosis, Is It Safe?

Moustafa MA*

Department of General and Thoracic Surgery, IDA hospital, Aleppo, Syria

***Corresponding author:**

Mohamed Alhaj Moustafa,
 Department of General and Thoracic Surgery,
 IDA hospital, Aleppo, Syria, Tel: +905050010001,
 +963933570715, E-mail: m_haj_m@hotmail.com

Received: 11 Aug 2021

Accepted: 21 Aug 2021

Published: 26 Aug 2021

Copyright:

©2021 Moustafa MA. This is an open access article distributed under the terms of the Creative Commons Attribution License, which permits unrestricted use, distribution, and build upon your work non-commercially.

Keywords:

CES Congenital Esophageal Stenosis; Esophageal Segmental Resection; Primary Esophageal Anastomosis; Esophageal Stenosis; Barrets Esophagus.

Citation:

Moustafa MA. Segmental Resection for Congenital Esophageal Stenosis, Is It Safe?. *Ame J Surg Clin Case Rep.* 2021; 3(11): 1-6

Abbreviations:

CES: Congenital Esophageal Stenosis; MW: Membranous Web; FMT: Fibromuscular Thickening; TBR: Tracheobronchial Remnants

1. Abstract

Two cases of mid- esophageal stenosis in children during one year in our hospital. Their story of progressive dysphagia and vomiting started since birth, at six to nine months old, an esophageal stenosis was diagnosed by contrast esophagogram. First case has vertebral anomaly, operated at age five years, while the second was without commitment anomalies, operated at age three years after 18 sessions of dilatation.

Esophageal segmental resection with primary end to end anastomosis have been done with a fantastic result, controversial of esophageal operations in adult where the operations usually are more radically and more invasive. pathology reports reveal that the mucosa in the two cases were columnar like stomach or colon controversial to literature reports which reveal that the mucosa is normal in congenital esophageal stenosis.

The cases under follow up.

2. Introduction

Esophageal stenosis is a clinical condition defined as a fixed narrowing of the esophagus. This condition can be congenital or acquired. Congenital Esophageal Stenosis (CES) is manifested as an intrinsic narrowing of the esophagus present at birth. Acquired esophageal strictures in children can be divided into the following categories: traumatic, inflammatory, peptic, and after surgery [1]. The incidence of the different etiologies varies between countries. In developing countries, caustic injuries are more frequent [2]. Congenital Esophageal Stenosis (CES) is a rare anomaly and etiology, with an incidence less than (5%) [3].

3. Background

(CES) is rare condition found in 1 per 25,000 to 50,000 live births, with a slight predominance in males. This congenital condition can be isolated or associated with a different malformation [1].

Congenital esophageal stenosis is congenital malformation; it is characterized by intrinsic narrowing of the esophagus secondary to congenital malformation of the wall architecture [4].

Nihoul-Fekete and colleagues proposed the most widely used classification scheme in 1989. They categorized CES into three subtypes [4].

Membranous web (MW): 16.2% occur most commonly in the upper/middle third of the esophagus.

Fibromuscular thickening (FMT): 53.8% occur mainly in the middle/lower third.

Tracheobronchial remnants (TBR):29.9% are typically found in the lower third of the esophagus.

In TBR there are remnants in the esophageal wall, including cartilage, tracheal glands, and respiratory epithelium. TBR is caused by defective embryologic separation of the primitive foregut from the respiratory tract with resultant sequestration of tracheobronchial precursor cells in the esophageal wall. Thus, CES with TBR may be associated with esophageal atresia or tracheoesophageal fistulas in infants [5].

Symptoms: Most commonly, infants present with symptoms of progressive dysphagia and vomiting (generally after the introduction of solid/semisolid foods around the age of six months [6],

aspiration pneumonias and growth retardation [7]. However, some patients may have only intermittent symptoms and eventually seek medical attention during adulthood because of worsening dysphagia, chest pain, or recurrent food impactions [5].

3.1. Symptoms are typically investigated using:

- Contrast esophagogram, which often reveals a distinct esophageal narrowing, additionally, the proximal esophagus can become dilated over time.

-Endoscopy is usually the next investigation and an esophageal narrowing with normal mucosa is typically found.

- Recently, Endoscopic Ultrasound (EUS) being used to help diagnose CES, particularly TBR and FMT subtypes.

- Additional studies helpful in differentiating CES from achalasia and strictures caused by GERD include esophageal manometry and pH monitoring [6].

3.2. Management of these lesions include

- Endoscopic dilatation should be considered the first line of treatment, FMH and MD had good response rate to endoscopic or radiologic guided dilatation [8].
- Surgical repair in patient's resistant to dilatation, with known TBR subtype, or those with complications.
- Resection of the stenosis followed by end-to-end esophageal anastomosis is a general surgical treatment [7].
- Complications including an iatrogenic esophageal perforation following bougienage and leakage after segmental resection and reconstruction of the esophagus have been reported.
- While good prognosis has been reported following dilata-

tion and/or surgery when needed, it was also reported that dysphagia occurred frequently regardless of the therapeutic option at follow-up [7].

- Close, long-term follow-up is highly recommended [7].

Here I report two CES cases seen recently in our Hospital.

4. Case 1

Five years old Patient had progressive dysphagia since birthday, no other complained. His examination was within normal limits.

UGI Contrast study revealed Mid-esophageal stenosis (Figure 1).

Chest CT scan with contrast meal revealed deformity in T4, T5, T6 and mass like between mid-esophagus and the deformed vertebrae (Figure 2).

Thoracotomy was done trans fourth intercostal space and the esophagus isolated up and down the lesion then it dissected from the sever adhesion with vertebrae by sharp dissection.

The stenosis was about 2 cm with perforation in the posterior wall, resected and a primary anastomosis to the healthy esophagus was done with (Interrupted 3/0 vicryle) then a pleural flab from adjacent chest wall was prepared and wrapped about the anastomosis, chest tube inserted (Figure 3) and chest closed.

Patient went well without any complications.

At third day methylene blue test has done, no leak and the patient started to drink water. At fifth day chest tube removed and the patient discharged.

Follow up for one year without dysphagia.

Pathology report revealed that the resected stenotic esophageal segment has a gastric mucosa (Figure 4, 5).

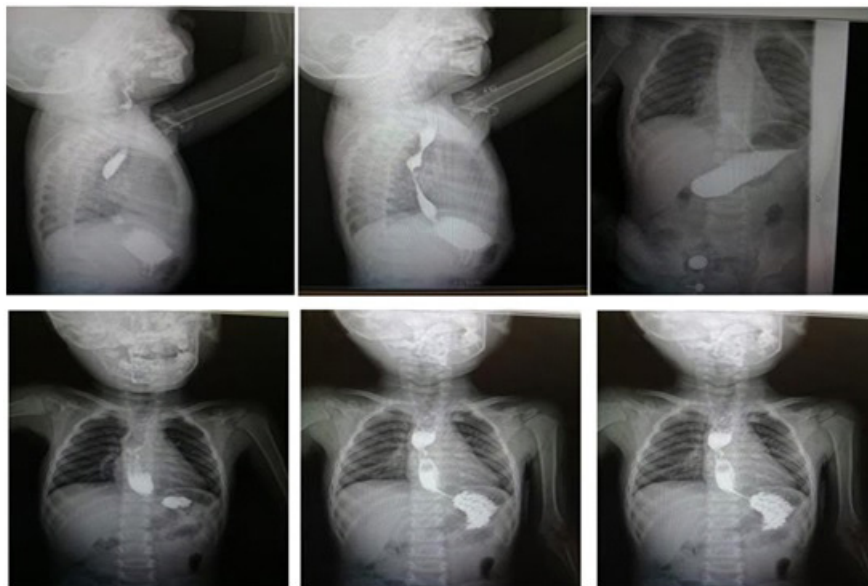


Figure 1: UGI Contrast study revealed Mid-esophageal stenosis

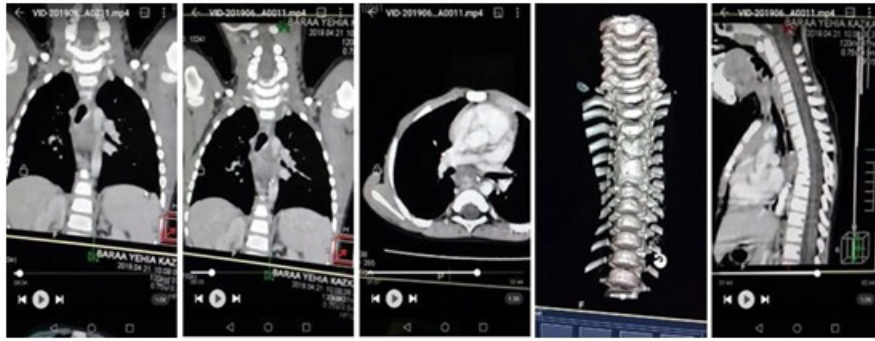

Figure 2: Chest Ct scan with contrast meal revealed deformity in T4, T5, T6 and mass like between mid-esophagus and the deformed vertebrae.

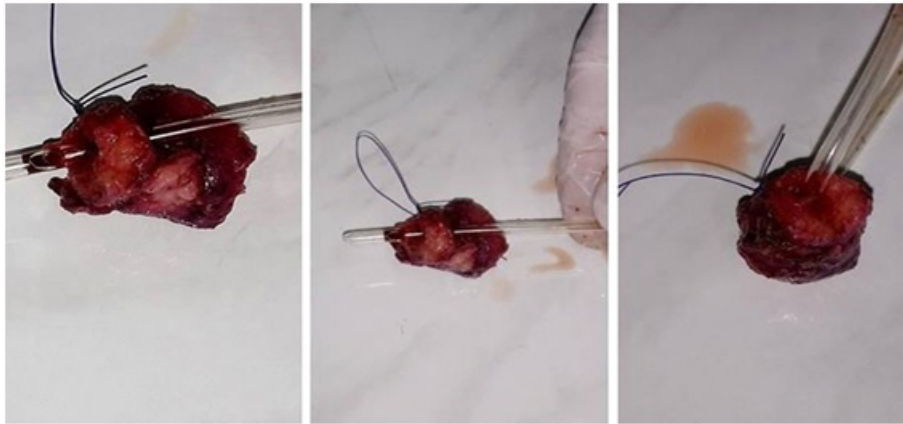


Figure 3: Resected Esophageal Segment



Figure 4: Pathology report.

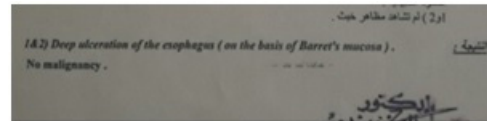


Figure 5: Pathology report.

5. Case 2

Three years old Female patient, healthy, has dysphagia and vomit-

ing since birthday. At nine months old, a mid-esophageal stenosis was diagnosed by contrast esophagogram and began sessions of balloon dilatation, esophageal perforation occurred during one of them, treated conservatively with chest tube and wide spectrum antibiotic. After ten sessions she referred to our hospital for Savary-Gilliard dilatation, eight sessions had done with intervals of 3-4 weeks without improvement. Follow up contrast esophgogram evaluation revealed a short segment stenosis in mid esophagus (Figure 1) and surgical intervention was decided.

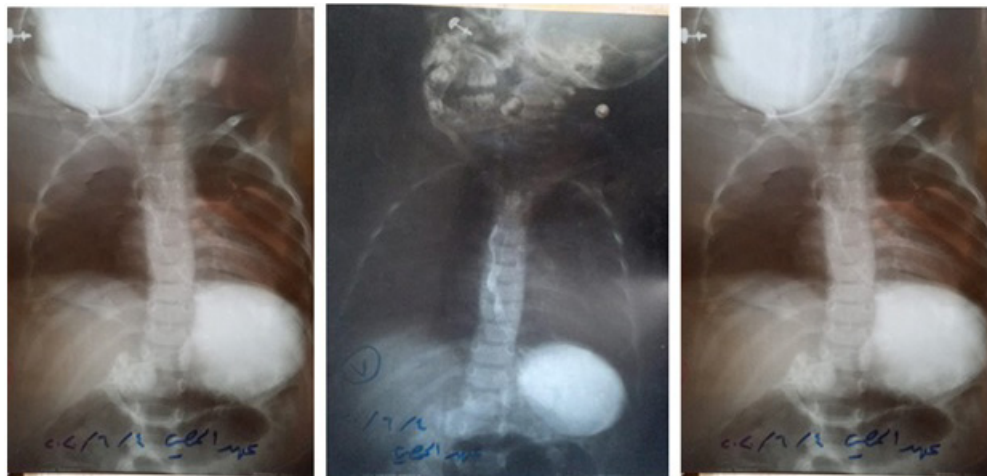

Figure 1: Contrast esophagogram, mid esophageal stenosis.

The operation has done with left lateral decubitus position through the right fifth intercostal space, the lung abducted anteriorly, the fibrotic segment of esophagus was evident, adhered to the right bronchus under azygous vein, pleura over esophagus opened, and azygous vein isolated on a sling, then esophagus isolated above and below the affected segment (Figure 2). The esophagus was cut above and below the segment (Figure 3), then the segment was resected sharply by cautery, its long about 2 cm, its wall is too thick, its mucosa was normal (Figure 4).

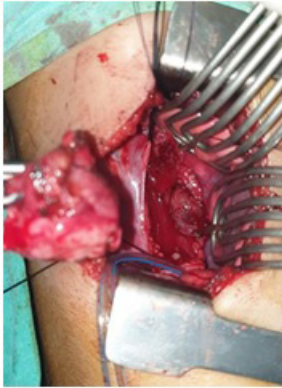

Figure 2: Isolation of Esophagus.

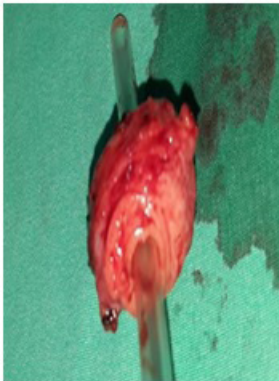


Figure 3: Resection of Esophageal Segment.

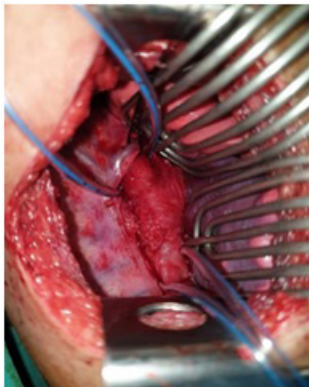


Figure 4: Resected Esophageal Segment

I reached to a healthy and normal wall thickness, stay Sutures were added to each corner, then the posterior line of the anastomosis was done by 3/0 vicryl interrupted Sutures with intervals of 0.5

cm (Figure 5). Then naso gastric tube inserted (Figure 6) and the anterior line completed in a same way. A pleural flap is prepared and wrapped around the anastomosis and fixed with many Sutures (Figure 7). Chest tube inserted, and chest wall closed.

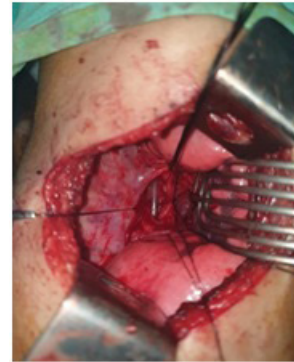

Figure 5: Posterior Wall of Anastomosis.

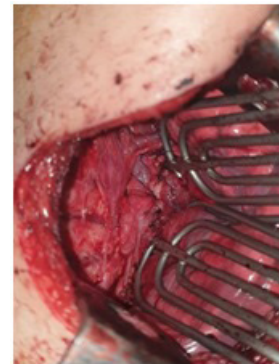

Figure 6: Insertion of NG Tube.

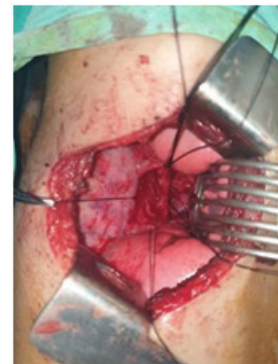

Figure 7: Completed Anastomosis with Pleural Flap.

Follow up went eventless, Patient kept NPO for five days, then methelin blue test done, no blue leakage found in the chest drain. Patient began to take fluids and after two days discharged on fluids regime for another one week after that advised to take a soft diet for one month.

Pathology report revealed that the resected stenotic esophageal segment has a gastric mucosa (Figure 8, 9).

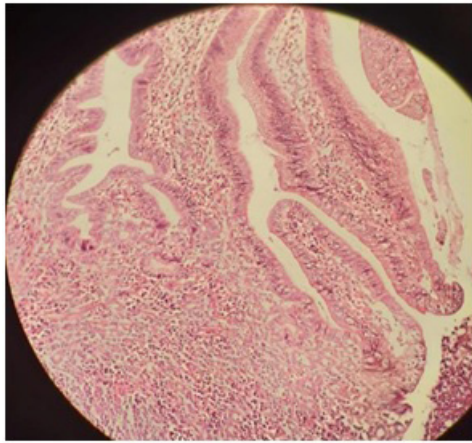


Figure 8: Pathology Report.

Number	18-235-2021	Patient name	Ahmed Alhomsi
Sex	F	Age	3 y
Site	Stomach	procedure	Excisional Biopsy from ulcer
date	31/1/2021	Doctor	
Gross:			
Cylinder piece measures 2.5 cm in diameter, cut sections show fibrous wall with presence of lumen			
Microscopic:			
Sections show benign mucosal gastric type glands, congestion, edema and mixed inflammatory infiltrate mainly neutrophils, with an ulcer lined by inflammatory granulation tissue and covered by purulent exudates. No presence of tissue from the esophagus.			
Diagnosis:			
Benign acute peptic ulcer, no malignancy.			
Pathologist Yahya Khalil MD			

Figure 9: Pathology Slid.

6. Discussion

Esophagus is a long tube-like organ stretched from pharyngus in the neck to stomach in the abdomen through posterior mediastinum in the chest. Anatomically, it has special features that make dealing surgically with it full of dangers.

- Its blood supply in chest is segmental by branches of aorta, proximal and distal ends of esophagus cannot be dissected too far to gain some elongation so some anastomosis may be under tension with tendency to break down.
- It has not serosa, so it so easy to leak then fistula occur.
- It transmits saliva which is full of amylase, so the leakage to chest is miserable.
- It is innervated by the esophageal plexus, which is formed by a combination of parasympathetic vagal trunks and sympathetic fibers from cervical and thoracic sympathetic trunks, so esophageal resection leads to motility disorders.
- It has a very vital relation in neck, chest and abdomen, so esophageal operations are always hard and dangerous and surgeons deal with esophagus carefully and cautiously.

Most dangerous complications happen when the procedure in chest, so surgeons try to do anastomosis far of chest, in neck or abdomen.

For that reasons, when the lesion is short and limited, segmental esophageal resection with primary anastomosis must be indicated, and more radical operations must be excluded because it is less invasive, less time consuming, more physiological, and less morbidity and mortality.

Pearson's Thoracic Esophageal Surgery advice is: the esophagus may be retained for patients with a relatively short-segment stricture [9].

Genc, Kadir et la advice is: In the surgical treatment of esophageal strictures, if possible, a stricture resection and primary anastomosis should be undertaken [10].

Shigeru Takamizawa et la. When CES patients fail to respond to repeated attempts of bougienage, surgical intervention should be considered. The stenotic lesion is detected by palpation with assistance of the fiber optic scop introduced through the mouth. A limited esophageal resection of the stenosis followed by end-to-end esophageal anastomosis is a general surgical treatment. Good outcome of circular myectomy has been also reported [11].

Unlike the resection of a CES where the anastomosis is performed in normal tissue on both sides of the malformation, the resection of a caustic stenosis is always done in an injured pathologic tissue and leads to recurrence of the stenosis as done under tension in a poorly vascularized tissue [12].

For safety, it is advisable to reinforce the anastomosis with a flap, the available flaps are:

In neck: strap muscles, skin with platysma muscle.

In chest: pleura, intercostal muscles, azygous vein.

In abdomen: diaphragm muscle, momentum.

Otherwise, regarding our two cases, I noticed some similar facts about the lesions:

1. The esophageal stenosis located at carina.
2. Its long about 1, 5- 2cm.
3. Sever adhesions to surrounding structures.
4. Its mucosa is not stratified as esophagus but columnar as stomach or colon.

While all literature reports assured that the mucosa in CES is normal, this leads to many questions:

1. Is this stenosis is actually CES?
2. Is it due to complication of ectopic mucosa?
3. Is it barret's esophagus due to congenital GERD?

I researched widely, but have not got the cure answer.

7. Conclusion

Although congenital esophageal stenosis CES is a rare anomaly, it must be in mind as a differential diagnosis of all cases of dysphagia and vomiting in children beside another commonly causes as GERD and achalasia. Main strategy in management is dilatation

in MW and MFT, whereas surgery indicated in TBR, dilatation failure and for complications.

The advisable surgical procedure is segmental esophageal stenosis with end to end primary anastomosis, it is unlike for caustic stenosis, safe and trusted, that the lesion is short and limited and the mucosa is normal and healthy. It has the advantages of being less invasive, less time consuming, more physiological, and less morbidity and mortality.

Close, long-term follow-up is highly recommended to roll out motility disorders and stenosis of anastomosis.

References

1. Brzački V, Mladenović B, Jeremić L, Živanović D, Govedarović N, Dimić D, et al. Congenital esophageal stenosis: a rare malformation of the foregut. *Nagoya J Med Sci.* 2019; 81: 535-547.
2. Urganci N, Usta M, Kalyoncu D, Demirel E. Corrosive substance ingestion in children. *Indian J Pediatr.* 2014; 81: 675-9.
3. Ranjan Dohil, Eric Hassall. Esophageal Stenosis in Children. *Gastrointestinal Endoscopy Clinics of North America.* Volume 8, Issue 2,1998, Pages 369-390.ISSN 1052-5157, [https://doi.org/10.1016/S1052-5157\(18\)30267-8](https://doi.org/10.1016/S1052-5157(18)30267-8).
4. Leesa MC, Dickenb BJ. Congenital esophageal stenosis in 3 children: A case series. *Journal of Pediatric Surgery Case Reports.* 2017; 23: 21-24.
5. Oh CH, Levine MS, Katzka DA, Rubesin SE, Pinheiro LW, Amygdalos MA, et al. Congenital Esophageal Stenosis in Adults: Clinical and Radiographic Findings in Seven Patients. *AJR.* 2001; 176.
6. Congenital Anomalies of the Esophagus, Carroll M. Harmon, Arnold G. Coran, in *Pediatric Surgery (Seventh Edition)*, 2012.
7. Nio Masaki, Amae Shintaro, Wada Motoshi. Congenital Esophageal Stenosis. [10.1007/978-3-642-38482-0_49-1](https://doi.org/10.1007/978-3-642-38482-0_49-1). 2017.
8. Soo-Hong Kim, Hyun-Young Kim. Congenital Esophageal Stenosis in Children: From Etiology to Prognosis. *J Korean Assoc Pediatr Surg.* 2018; 24(1): 1-4.
9. Pearson's Thoracic Esophageal Surgery 3rd Ed [PDF][tahir99] VRG page 764. PMID: 23608276 DOI: [10.1016/j.athoracsur.2012.11.063](https://doi.org/10.1016/j.athoracsur.2012.11.063)
10. Kadir G, Zeliha U, Güçlü C, Teoman S, Yilmaz M, Mutaf O, et al. Esophageal reconstruction in the treatment of caustic esophageal strictures in children. *Pediatric Cerrahi Dergisi.* 2001; 15: 115-119.
11. Takamizawa S, Tsugawa C, Mouri N, Satoh S, Kanegawa K, Nishijima E, et al. Congenital Esophageal Stenosis: Therapeutic Strategy Based on Etiology. *J Pediatr Surg.* 2002; 37: 197-201.